

See discussions, stats, and author profiles for this publication at: <http://www.researchgate.net/publication/237835801>

# Intraoperative pulmonary embolism during spinal instrumentation surgery

ARTICLE *in* ACOUSTICS, SPEECH, AND SIGNAL PROCESSING NEWSLETTER, IEEE · JANUARY 2003

DOI: 10.1302/0301-620X.85B1.13172

---

CITATIONS

20

---

DOWNLOADS

292

---

VIEWS

92



# Intraoperative pulmonary embolism during spinal instrumentation surgery

## A PROSPECTIVE STUDY USING TRANSOESOPHAGEAL ECHOCARDIOGRAPHY

S. Takahashi, H. Kitagawa, T. Ishii

From Nagahama City Hospital, Shiga, Japan

**I**ntraoperative pulmonary fat and bone-marrow embolism is a serious complication of bone and joint surgery. We have investigated the occurrence and incidence of intraoperative embolism in patients undergoing elective lumbar spinal surgery with or without instrumentation.

Sixty adult patients with lumbar degenerative disease were examined by intraoperative transoesophageal echocardiography while undergoing posterior lumbar surgery. Of these, 40 underwent surgery with instrumentation and 20 without.

Moderate to severe (grade 2 or 3 according to the grading scale of Pitto et al) embolic events were seen in 80% of the instrumented patients but in none of the non-instrumented patients ( $p < 0.001$ ). The insertion of pedicle screws was particularly associated with large numbers of pulmonary emboli, while the surgical approach, laminectomy, disc removal and bone harvesting were associated with small numbers of emboli.

We consider that, as in arthroplasty and intramedullary fixation of fractures, these embolic events are relevant to the development of potentially fatal fat embolism during spinal surgery.

*J Bone Joint Surg [Br]* 2003;85-B:90-4.  
Received 17 January 2002; Accepted 6 March 2002

Intra- or perioperative fat embolism is a potentially fatal complication of bone and joint surgery. This iatrogenic embolism is caused by fat and bone-marrow emboli pro-

duced by the pressurisation and manipulation of the intramedullary canals of long bones, and is a serious concern among orthopaedic surgeons and anaesthetists involved in the fixation of fractures or joint replacement surgery.<sup>1-13</sup> In spinal surgery, there have been reports of fatalities caused by a similar complication associated with instrumentation,<sup>14-17</sup> but the pathomechanism remains uncertain. Since there is an increasing use of implants in spinal surgery, it is important to determine the incidence of intraoperative pulmonary fat and bone-marrow embolism accompanying their insertion. We have therefore investigated the occurrence and incidence of pulmonary embolism during spinal surgery by monitoring with transoesophageal echocardiography.

### Patients and Methods

We studied prospectively 40 consecutive patients undergoing spinal instrumentation for degenerative lumbar spinal disorders by intraoperative transoesophageal echocardiography (instrumentation group). Those with a spinal tumour or trauma were not included. There were 16 men and 24 women with a mean age of 57 years (28 to 77). The diagnosis was degenerative spondylolisthesis in 13, degenerative scoliosis in eight, recurrent disc herniation in five, primary disc herniation in four, painful kyphotic deformity in four, spondylolytic spondylolisthesis in three and other causes in three. The preoperative physical status of the patients was categorised into classes from 1 to 5 according to the criteria of the American Society of Anesthesiologists (ASA).<sup>18</sup> Preoperative informed consent was obtained from each patient with regard to the intraoperative examination with echocardiography.

All the operations were performed under general anaesthesia using a midsagittal posterior approach with the patient placed in a prone position on a four-point frame allowing abdominal decompression. In each patient, we inserted a 5 MHz transoesophageal multiplane ultrasound probe (Aloka, Japan) after endotracheal intubation, and continuous intraoperative monitoring was performed with a mid-oesophageal view allowing visualisation of the four chambers of the heart, which was videotaped. Routine intraoperative monitoring included blood pressure, heart rate, electrocardiography, end-tidal CO<sub>2</sub> concentration, and oxygen saturation measured by pulse oximetry.

S. Takahashi, MD, Lecturer  
Department of Orthopaedics  
H. Kitagawa, MD, Assistant Professor  
Department of Anesthesiology  
Shiga University of Medical Science, Seta-Tsukinowa-cho, Ohtsu-shi, Shiga 520-2192, Japan.

T. Ishii, MD  
Department of Anesthesiology, Nagahama City Hospital, 313 Ooinui-cho, Nagahama-shi, Shiga 526-8580, Japan.

Correspondence should be sent to Dr S. Takahashi.

©2003 British Editorial Society of Bone and Joint Surgery  
doi:10.1302/0301-620X.85B1.13172 \$2.00

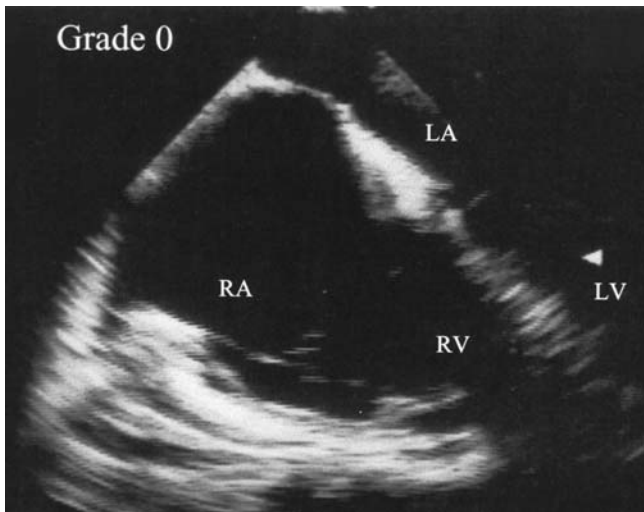


Fig. 1a

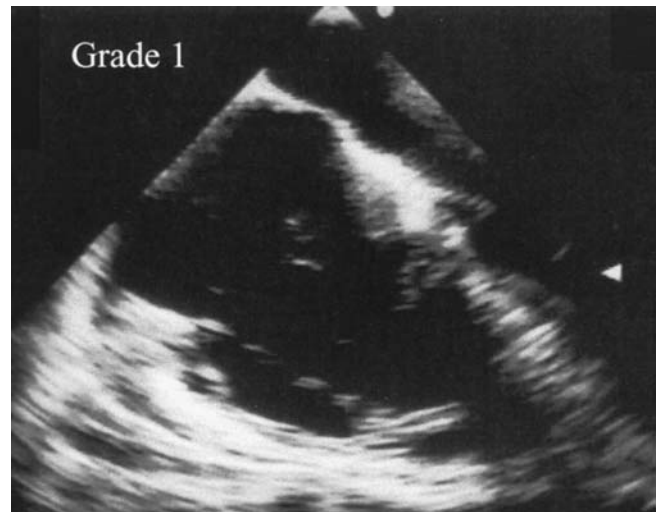


Fig. 1b

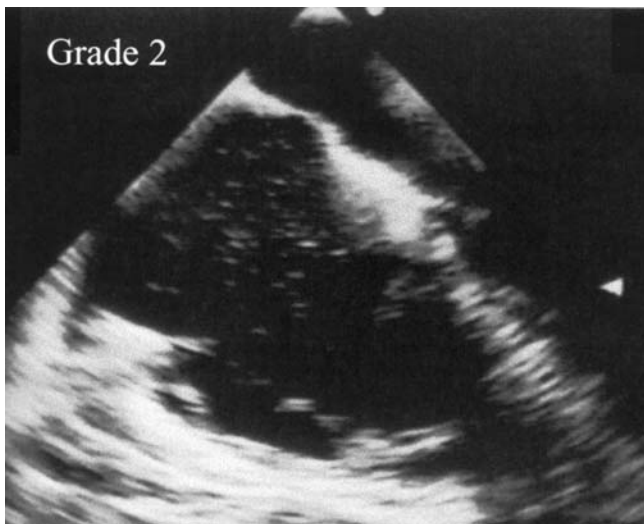

Fig. 1c

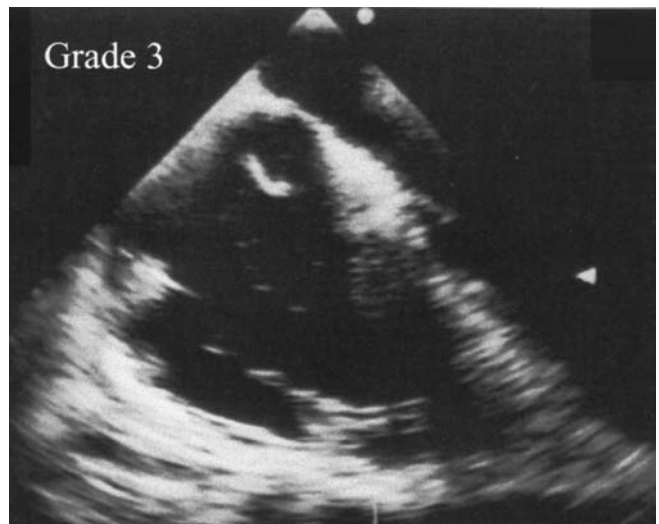

Fig. 1d

Embolic events observed and graded on transoesophageal echocardiography showing a) grade 0, no emboli observed, b) grade 1, a few fine emboli in the right atrium, c) grade 2, embolic events with a cascade or shower of numerous fine embolic echoes seen after the insertion of lumbar pedicle screws, and d) grade 3, embolic events with a serpentine macroembolus greater than 5 mm among fine emboli.

All patients first underwent partial or wide laminectomy at the levels responsible for the neurological symptoms. Instrumentation for fixation and/or correction was performed, and was followed by bone grafting. All the instrumentations were posterior, comprising pedicle screws and rods. A small number of laminar hooks were added in two patients and intervertebral cages for interbody fusion in 15. The number of fused levels was one in 21 patients, two in 16, three or more in three, with a mean of 1.6 levels for all patients. In all patients undergoing a single-level fusion, it was achieved by a posterior lumbar interbody technique. In the 16 patients undergoing a two-level fusion, there were ten posterior interbody fusions, one posterolateral fusion, and five combinations of posterior interbody and posterolateral

fusion. Two of the three patients undergoing a fusion at three or more levels had a posterolateral fusion and one had a combination of posterior interbody and posterolateral fusions. Local bone fragments generated from the laminectomy were used as bone grafts in all patients. In 22 patients additional bone grafts were harvested from a posterior iliac crest. The number of pedicle screws used per patient ranged from four to ten with a mean of 5.1. Self-tapping screws were inserted after probing within the pedicle with a small curette or probe and confirming the position and direction by radiographic control. The diameter of the pedicle screws was 6.5 mm for the lumbar vertebrae and 5.5 mm for the lower thoracic vertebrae. In all patients, bilateral transpedicular fixation was performed using a rod on each side.

During the same period, a control group of 20 other patients with degenerative lumbar spinal disorders who had undergone lumbar spinal surgery without instrumentation was examined in the same way. There were 14 men and six women with a mean age of 61 years (34 to 80). The diagnosis was disc herniation in ten patients, spinal stenosis in nine and unstable disc degeneration in one. The operative procedures included a partial or wide laminectomy with or without discectomy in 18 patients and a non-instrumented lumbar fusion with local or iliac bone grafts in two.

No anticoagulant prophylaxis was given before or during the operation in any of the 60 patients. Low-dose aspirin was given to all patients for 14 days after operation. All patients in both groups were mobilised between the second and fourth postoperative days.

All recorded data were reviewed and analysed by anaesthetists (HK, TI) who were trained in echocardiography, to whom the data were blinded during analysis. The patterns of emboli observed during operation were classified according to the grading scale of Pitto, Koessler and Draenert<sup>19</sup> which has been described for hip replacement (Fig. 1) as follows: grade 0, no emboli; grade 1, a few fine emboli; grade 2, a cascade of fine emboli or embolic masses with a diameter not exceeding 5 mm; and grade 3, fine emboli mixed with embolic masses with a diameter of more than 5 mm.

**Statistical analysis.** Intergroup comparison of mean values was performed using the Mann-Whitney rank-sum test and that of proportions of different grades by the chi-squared test. Differences were considered to be significant when the *p* value was less than 0.05.

## Results

In the instrumentation group the preoperative ASA physical status was class 1 for 12 patients, class 2 for 27 and class 3 for one and in the control group class 1 for seven and class 2 for 13. There was no significant difference between the groups with regard to age, gender and preoperative physical status. The mean duration of the operation was significantly longer ( $p < 0.001$ ) in the instrumentation group (222 minutes) than in the control group (86 minutes). The mean intraoperative blood loss was significantly greater ( $p <$

0.001) in the instrumentation group (457 g *v* 83 g). No allotransfusion was performed in any patient in either group.

The relationships between the operative procedures and the embolic events seen on transoesophageal echocardiography are summarised in Table I. Moderate to severe embolic echoes, i.e. grade-2 or grade-3 embolic events, were seen in 32 (80%) patients in the instrumentation group during and shortly after the insertion of pedicle screws. In most cases, a small number of fine embolic echoes began to enter the right atrium and ventricle shortly after probing within a vertebral body through its pedicle. Then, as the screw was inserted more and more fine embolic echoes appeared, forming a cascade or a snowstorm-like appearance. Such events continued during the successive insertion of screws and until between one and 15 minutes after the insertion of the last screw. In six patients in the instrumentation group, embolic masses larger than 5 mm (6 mm to 20 mm) in diameter were observed (Pitto grade 3) among the cascade. Of these, five showed large masses during or immediately after insertion of a screw and one during the tightening procedure of the screw-rod construct approximately 45 minutes after insertion of a screw. A small proportion of patients in the same group showed grade-1 embolic events during laminectomy, removal of intervertebral disc material, or harvesting of iliac bone graft. In these instances, a few echoes appeared shortly after tapping the bone with a hammer and chisel. Embolic echoes were not seen in any patients during soft-tissue dissection.

In the control group no grade-2 or grade-3 embolic phenomena were observed. Four patients showed a few fine emboli (grade 1) during laminectomy using a chisel while the other 16 had no pulmonary embolism throughout the operation. There was a significant difference between the two groups with regard to the grade of embolic events ( $p < 0.001$ ).

No patient in either group had a significant alteration in blood pressure, heart rate, electrocardiography, end-tidal CO<sub>2</sub> or oxygen saturation intraoperatively which synchronised with the embolic events seen on echocardiography. No perioperative systemic or local complication was encountered in any patient in either group, except for one in the

**Table I.** The relationship of the operative procedure and the incidence of embolic events

Operative procedure	Instrumentation group (n = 40)				Control group (n = 20)			
	Grade 0	Grade 1	Grade 2	Grade 3*	Grade 0	Grade 1	Grade 2	Grade 3*
Exposure of vertebrae	40/40	0/40	0/40	0/40	20/20	0/20	0/20	0/20
Laminectomy	30/40	10/40	0/40	0/40	16/20	4/20	0/20	0/20
Removal of intervertebral disc(s)	36/38	1/38	0/38	0/38	12/12	0/12	0/12	0/12
Harvesting iliac bone grafts	20/22	2/22	0/22	0/22	1/1	0/1	0/1	0/1
Insertion of pedicle screws	0/40	8/40	27/40	5/40	NP†	NP	NP	NP
Insertion of rods, hooks, or cages	39/40	0/40	0/40	1/40	NP	NP	NP	NP
Closure of wounds	40/40	0/40	0/40	0/40	20/20	0/20	0/20	0/20
Entire operative procedure‡	0/40	8/40	26/40	6/40	16/20	4/20	0/20	0/20

\*grading scale of embolic events according to Pitto et al<sup>19</sup>

†not performed

‡a significant difference was detected between the two groups ( $p < 0.001$ ) by the chi-squared test

instrumentation group who had a transient arrhythmia (atrial paroxysmal contraction) in the absence of hypotension or hypoxaemia which began four hours after the operation and lasted about six hours, with no sequelae.

## Discussion

Sudden intraoperative or perioperative cardiopulmonary dysfunction as a result of fat embolism is a well-known complication of bone and joint surgery. In such cases the embolism is thought to be related to the insertion of a stem or a rod into the intramedullary canal of a long bone, typically during cemented fixation of a femoral stem during total hip arthroplasty.<sup>6-9,11-13,19</sup> In our study, it was noted that the insertion of spinal implants, particularly pedicle screws, resulted in intraoperative pulmonary embolism similar to that seen during arthroplasty and fixation of intramedullary fractures. Laminectomy, discectomy and bone harvesting did not markedly produce emboli. The exact clinical relevance of this embolism needs to be further investigated. There have been reports of fatal peri-operative fat embolism associated with spinal instrumentation,<sup>14-17</sup> and we speculate that some cases may be attributable to the use of implants.<sup>16,17</sup> Based on our results, it seems probable that at least some of the intraoperative cardiopulmonary complications which are seen during spinal instrumentation are a result of implant-related embolism. As with arthroplasty, we hypothesise that patients with preoperative cardiopulmonary comorbidities may be more vulnerable to intraoperative fat embolism. Clinically, the number of patients who suffer fatal intraoperative fat embolism is probably larger than has been reported since such cases are usually undiagnosed.

We were surprised by the large amount of emboli observed in our patients considering the size of the pedicle screws relative to the vertebral volume. It also seemed that the duration of the embolism, which lasted for 15 minutes in several patients, was long compared with the short time taken to insert the screws and the reason for this remains unclear. The paravertebral venous system, known as Batson's plexus, may be different from that of the limbs, and perhaps the marrow-vessel barrier has a looser structure in the thoracolumbar vertebrae, facilitating the intravasation of fat and marrow tissues after medullary damage. We hypothesise that the genesis of embolic masses as large as 20 mm or more may be due to activated intravascular coagulation combined with venous stasis within the local venous plexus, which may generate macroemboli comprising fat, bone marrow and thrombi, as has been suggested in fractures and arthroplasties in the lower limbs.<sup>13,19</sup> This may explain the early postoperative pulmonary fat embolism in elective spinal instrumentation surgery.<sup>15,16</sup>

Several further questions remain to be addressed. First, the incidence of intraoperative embolism in spinal surgery is not known. Experience suggests that the incidence of severe intraoperative cardiopulmonary complications may be simi-

lar for both arthroplasty and spinal surgery. Complications due to undiagnosed embolism during spinal surgery may be more common than has been assumed, and a review of the literature revealed that the perioperative mortality rate of lumbar spinal surgery with pedicle screws varies between 0% and 1.5% with a mean of between 0.7% and 0.8%.<sup>20</sup> Secondly, the nature of the emboli should be confirmed. In spinal surgery, no identification of the content of the emboli has been undertaken, whereas emboli occurring during arthroplasty have been shown to contain fat and bone-marrow cells.<sup>21,22</sup> Thirdly, the severity of fat embolism should be assessed more objectively. The embolism is sub-clinical in most patients. Pulmonary perfusion scintigraphy or detailed circulatory monitoring including measurement of pulmonary arterial pressure<sup>23</sup> may be useful in evaluating the subclinical cardiopulmonary compromise. Fourthly, identification of patients who are at risk is important from a point of view of prophylaxis. In the present series, in the instrumentation group, women had emboli of a higher grade than men, but this difference was not statistically significant. It also seemed that an osteoporotic spine produced more emboli than a spine with sclerotic changes, but again without statistical significance. A larger series will be needed to identify the subgroup of patients who have a high risk of embolism. Finally, methods of preventing embolism in high-risk patients need to be developed. Once pedicle screws have been selected, prevention of embolism is difficult. We suggest that decompression of the vertebral body in some way during insertion of screws, filtration within the inferior vena cava or anticoagulant prophylaxis may decrease embolism. Further investigation is required for the safer use of spinal instrumentation, especially pedicle screws. Spinal surgeons, anaesthetists and intensive-care physicians should be aware of occult pulmonary embolism occurring during spinal instrumentation surgery, which may possibly lead to severe or even fatal complications in a very small number of patients, as in arthroplasty.

The authors thank Drs Y. Kotoura, T. Ishibe, Y. Shima, K. Takahashi, N. Iwashita and Y. Imashuku for their cooperation.

No benefits in any form have been received or will be received from a commercial party related directly or indirectly to the subject of this article.

## References

1. Aoki N, Soma K, Shindo M, Kurosawa T, Ohwada T. Evaluation of potential fat emboli during placement of intramedullary nails after orthopedic fractures. *Chest* 1998;113:178-81.
2. Bracco D, Favre J-B, Joris R, Ravussin A. Fatal fat embolism syndrome: a case report. *J Neurosurg Anesthesiol* 2000;12:221-24.
3. Bulger EM, Smith DG, Maier RV, Jurkovich GJ. Fat embolism syndrome: a 10-year review. *Arch Surg* 1997;132:435-9.
4. Forteza AM, Koch S, Romano JG, et al. Transcranial doppler detection of fat emboli. *Stroke* 1999;30:2687-91.
5. Heine TA, Halambeck BL, Mark JB. Fatal pulmonary fat embolism in the early postoperative period. *Anesthesiology* 1998;89:1589-91.
6. Herndon JH, Bechtol CO, Crickenberger DP. Fat embolism during total hip replacement: a prospective study. *J Bone Joint Surg [Am]* 1974;56-A:1350-62.
7. Levy D. The fat embolism syndrome: a review. *Clin Orthop* 1990;261:281-6.



8. Orsini EC, Byrick RJ, Mullen JBM, Kay JC, Waddell JP. Cardiopulmonary function and pulmonary microemboli during arthroplasty using cemented or non-cemented components: the role of intramedullary pressure. *J Bone Joint Surg [Am]* 1987;69-A:822-32.
9. Patterson BM, Healey JH, Cornell CN, Sharrock NE. Cardiac arrest during hip arthroplasty with a cemented long-stem component: a report of seven cases. *J Bone Joint Surg [Am]* 1991;73-A:271-7.
10. Pinney SJ, Keating JF, Meek RN. Fat embolism syndrome in isolated femoral fractures: does timing of nailing influence incidence? *Injury* 1998;29:131-3.
11. Pitto RP, Koessler M, Kuehle JW. Comparison of fixation of the femoral component without cement and fixation with use of a bone-vacuum cementing technique for the prevention of fat embolism during total hip arthroplasty: a prospective, randomized clinical trial. *J Bone Joint Surg [Am]* 1999;81-A:831-43.
12. Hofmann S, Huemer G, Salzer MP. Pathophysiology and management of the fat embolism syndrome. *Anaesthesia* 1998;53 Suppl, 2:35-7.
13. Mellor A, Soni N. Fat embolism. *Anaesthesia* 2001;56:145-54.
14. Brown LP, Stelling FH. Fat embolism as a complication of scoliosis fusion. *J Bone Joint Surg [Am]* 1974;56-A:1764.
15. Gittman JE, Buchanan TA, Fisher BJ, Bergeson PS, Palmer PE. Fatal fat embolism after spinal fusion for scoliosis. *JAMA* 1983;249:779-81.
16. Brandt SE, Zeegers WS, Ceelen ThL. Fatal pulmonary fat embolism after dorsal spinal fusion. *Eur Spine J* 1998;7:426-8.
17. Watanabe K, Kumano K, Machida H, et al. Fatal bone marrow embolism in corrective osteotomy of ankylosing spondylitis with spinal instrumentation: a case report. Proc 8th Annual Meeting of Japan Society for the Study of Surgical Technique for Spine and Spinal Nerves. 2001, 146-7..
18. American Society of Anesthesiologists. New classification of physical status. *Anesthesiology* 1963;24:111.
19. Pitto RP, Koessler M, Draenert K. Prophylaxis of fat and bone marrow embolism in cemented total hip arthroplasty. *Clin Orthop* 1998;355:23-4.
20. Brantigan JW, Steffee AD, Lewis ML, Quinn LM, Persenaire JM. Lumbar interbody fusion using the Brantigan I/F cage for posterior lumbar interbody fusion and the variable pedicle screw placement system: two-year results from a Food and Drug Administration investigational device exemption clinical trial. *Spine* 2000;25:1437-46.
21. Christie J, Burnett R, Potts HR, Pell ACH. Echocardiography of transatrial embolism during cemented and uncemented hemiarthroplasty of the hip. *J Bone Joint Surg [Br]* 1994;76-B:409-12.
22. Woo R, Minster GJ, Fitzgerald RH Jr, et al. Pulmonary fat embolism in revision hip arthroplasty. *Clin Orthop* 1995;319:41-53.
23. Urban MK, Urquhart B, Boachie-Adjei O. Evidence of lung injury during reconstructive surgery for adult spinal deformities with pulmonary artery pressure monitoring. *Spine* 2001;26:387-90.